



Evaluation of Eustachian Tube Function in the Early Postoperative Period after Endoscopic Radiofrequency Adenoidectomy in Children

Al Hussein Awad ¹, Mostafa Youssif ², Mohammad Aouf ³, Ragaey Youssef ⁴, Saad Elzayat ³

1. Otorhinolaryngology Department, Faculty of Medicine, Sohag University

2. Audiovestibular Medicine, Faculty of Medicine- Sohag University, Egypt

3. Otorhinolaryngology Department Faculty of medicine Kafrelsheikh university

4. Audio-vestibular medicine , Faculty of medicine Beni-Suef university

Abstract:

Background: Adenoidectomy is one of the most frequently performed surgeries in paediatric otolaryngology. Endoscopic radiofrequency adenoidectomy is a relatively new technique to achieve improved visualization and better haemostatic control compared to the traditional curettage adenoidectomy with expected better outcomes. This study was done to assess the changes in the middle ear pressure in children with normal preoperative middle ear pressure and adenoid enlargement during the early postoperative period following endoscopic radiofrequency adenoidectomy.

Patients and Methods: 40 children with adenoid hypertrophy and normal tympanogram who had endoscopic radiofrequency adenoidectomy were included in this prospective study. Tympanometry was done before surgery and again on the first, third, and seventh postoperative days with the results being compared.

Results: the patients in this study consisted of 24 males and 16 females, with an age range from 4 to 12 years and a mean age of 7 years. On the first postoperative day, 14 (35%) patients had pathological declines in at least one ear's middle ear pressure, followed by 8 (20%) patients on the third postoperative day, and by the seventh postoperative day, the middle ear pressure (MEP) had restored to its preoperative level. On the first- and third-days following surgery, there was a statistically significant difference between MEP in both ears compared to the preoperative one, while on the seventh day MEP showed no statistically significant difference.

Conclusion: Following endoscopic radiofrequency adenoidectomy in children, transient and temporary negative middle ear pressure without hearing loss occurs in the early postoperative phase.

Keywords: Radiofrequency, Adenoidectomy, Eustachian Tube, Middle ear pressure, Tympanometry.

Introduction

In the practice of pediatric otorhinolaryngology, adenoidectomy is one of the most frequently performed

surgeries.¹ The primary indications for adenoidectomy include nasal obstruction with chronic mouth

breathing, recurrent rhinosinusitis, and otitis media with effusion, snoring, recurrent otitis media, and obstructive sleep apnea caused by adenoid enlargement.²

The goal of the optimal adenoidectomy surgery is to remove the adenoid completely and safely with the least amount of blood loss, minimal postoperative morbidity, and the quickest possible recovery.³ Although the traditional method of performing adenoidectomy by adenoid curette is straightforward and well-established, it is a blind process and is linked to risks such as hemorrhage, insufficient removal, excessive curettage, and injury to the Eustachian tube (ET) and cervical spine.⁴

Due to dissatisfaction with the curettage adenoidectomy, new surgical techniques for removing adenoid tissue have been developed to ensure better hemostatic control with improved visualization, guarantee complete removal of the adenoid bulk, and protection against potential harm.^{5,6} Laser ablation, radiofrequency ablation, suction diathermy, coblation wand, and microdebrider are just a few of the endoscopic assisted adenoidectomy techniques that have emerged as a result of the increased usage of intranasal endoscopy.^{7,8}

Radiofrequency volumetric tissue reduction technology, which promotes mucosal and submucosal scarring and adenoid size reduction with less tissue damage and painless effects, is one of the merits of radiofrequency over other electric techniques.⁹

This prospective study was carried out to assess changes in the middle ear pressure in pediatric patients with adenoid enlargement and preoperatively normal middle ear pressure following endoscopic radiofrequency adenoidectomy.

Patients and Methods

Ethical considerations

Before the study, the local ethical committee gave its approval, and the patient's legal representatives gave their written informed consent. The study was carried out by following the Helsinki Declaration's principles.

Patient selection and study design

Forty children with adenoid hypertrophy underwent endoscopic radiofrequency adenoidectomy (multicenter) between March 2022 and July 2022 as part of this prospective trial. For this investigation, only children with a type A preoperative tympanogram and a normal tympanic membrane were taken into account. Any ear condition, pre-existing anomalies such as craniofacial abnormalities or cleft palate (frank, submucosal, repair), neuromuscular diseases, velopharyngeal insufficiency, bleeding or coagulation defects, or previous adenoidectomy, tonsillectomy, or ear surgery were all grounds for exclusion from this study.

Through meticulous history collecting, the patient's details, including age, sex, nasal, aural, and throat symptoms, were obtained. Each subject in this study underwent a thorough ENT examination. The clinical diagnosis of adenoid hypertrophy was confirmed using a flexible fiberoptic nasopharyngoscopy Olympus (w103275) and a plain X-ray lateral picture of the nasopharynx. Following surgery, the patients were asked if they had any post-operative problems, such as otalgia, auditory fullness, or hearing loss.

Surgical techniques

The procedure was carried out utilizing a (45-degree) endoscope (Karl Storz Hopkins ® II Optik endoscope, 18 cm long, 4 mm in diameter) and a Storz IMAGE 1 SPIES HD camera under general anesthesia and transoral

endotracheal intubation. We used the RF Ellman Surgitron (4 MHz) for adenoid ablation (Ellman International, New York, USA). The patient arrived in a supine position. The mouth was maintained open by using the Boyle Davis mouth gag. Two catheters that were put through the nose, taken out through the mouth, and knotted just above the top lip were used to retract the soft palate.

A 45-degree endoscope was then inserted into the oral cavity to see the nasopharynx. The adenoid pad was dried with gauze before starting the ablation. A 9-cm-long radiofrequency angled adenoid blade with a 40-degree angle was gently introduced via the oral canal, and the adenoid was removed starting low in the nasopharynx and moving side to side till the vomer.

The remaining adenoid tissue was suctioned out after reduction by the surgeon. Small adenoid tissue remnants were eliminated using suction radiofrequency probes operating in the same 7-W mode if they were discovered close to the ET orifice or at a high site at the choanal portion. Coagulation will be used, if necessary, to achieve hemostasis. The process involved no packing. After the nasal catheters and Boyle-Davis mouth gag were taken out, the patient emerged from general anesthesia.

Tympanometry

Preoperative and postoperative measurements of the middle ear pressure MEP were taken using the Tympanometry Interacoustics AT235 (Audiometer Alle', Middlefart, Denmark). The instrument used 226 Hz probe tones with negative and positive pressure sweeps between +200 and -400 daPa/s. Tympanometry was performed preoperative on the day of the procedure and once more on the first, third, and seventh days following the procedure. Tympanograms were classified (A, B,

and C) according to Jerger Classification. 10

Statistical analysis:

Data analysis was performed using SPSS Version 28 software (SPSS Inc., Chicago, Illinois, USA). Quantitative variables were expressed as mean \pm SD (standard deviation). A p-value < 0.05 was considered statically significant. A highly significant difference is present if $P \leq 0.001$.

Categorical variables were described using their absolute frequencies, and the chi-square test was used when appropriate to compare the proportion of categorical data. The Student *t*-test and repeated measures ANOVA tests were used when appropriate to compare preoperative and postoperative quantitative data that follow a normal distribution.

Results

From March 2022 to July 2022, 40 children with adenoid hypertrophy underwent endoscopic radiofrequency adenoidectomy (multicenter). There were 16 female patients and 24 male patients. The patients ranged in age from 4 to 12, with the mean age being 7 years. All patients had normal tympanic membranes and preoperative type A tympanogram (Table 1).

Tympanograms of type C were identified as abnormal and connected to malfunction of the ET. On the first postoperative day, 14 (35%) children had at least one ear with ET dysfunction, 10 (25%) had unilateral and 4 (10%) had bilateral ET dysfunction. None of the children had Type B tympanogram.

On the third postoperative day, unilateral Eustachian dysfunction was detected in 6 (15%) children, and bilateral ET dysfunction was detected in 2 (5%) children. On the seventh postoperative day, ET dysfunction was

not detected, and all children (100%) had type A tympanogram (Table 2).

There was a statistically significant difference between middle ear pressure preoperatively compared to postoperative middle ear pressure on the first and third days in both ears (Tables 3 and 4), even though there was no statistically significant variation from the middle ear pressure on the seventh day (Table 5).

Additionally, there were no statistically significant variations in middle ear pressure between the right and left ears before surgery or on the first, third, or seventh postoperative day (Tables 3, 4, and 5).

On the first postoperative day, a decrease in MEP was noticed in both ears. MEP began to rise on the third postoperative day and reverted to preoperative levels by the seventh postoperative day (Figure 1). Finally, none of the patients complained of otalgia, aural fullness, and hearing loss.

Table (1) Demographic and Preoperative Baseline Data of the Patients

Number of patients (n)	40
Gender (Male/Female)	24(60%)/16(40%)
Age Years (mean)	7 years
Preoperative Tympanic membrane status	Normal (100%)
Preoperative Tympanogram	Type A (100%)

Table (2) Results of postoperative tympanograms.

	Type A Tympanogram		Type C Tympanogram		Type B Tympanogram	
	Unilateral	Bilateral	Unilateral	Bilateral	Unilateral	Bilateral
First postoperative day	10 (25%)	26 (65%)	10 (25%)	4 (10%)	0	0
Third postoperative day	6 (15%)	32 (80%)	6 (15%)	2 (5%)	0	0
Seventh postoperative day	0	40 (100%)	0	0	0	0

Table 3: Comparison between ME pressure (dapa) obtained on the preoperative and the 1st postoperative day.

Ear side	Preoperative MEP	Post-operative 1 st day MEP	P-Value
Right	-14.25/ ± 28.98	-104.75 ± 86.29	< 0.05*
Left	-13.75 ± 28.42	-103.5 ± 75.08	< 0.05*
P-Value	0.839	0.811	

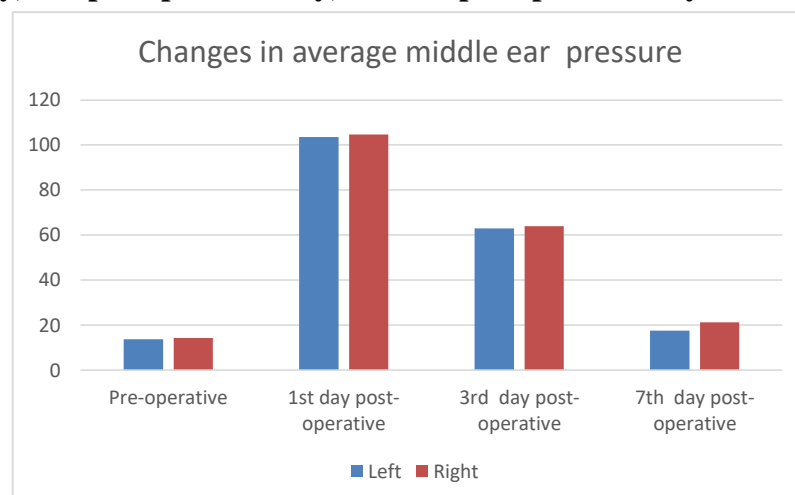
*p<0.05 is statistically significant

Table (4) Comparison between the Middle ear pressures (daPa) measured preoperative and on the 3rd post-operative day.

Ear side	Preoperative MEP	Postoperative 3 rd day MEP	P-Value
Right	-14.25/ ± 28.98	-64 ± 51.65	< 0.05
Left	-13.75 ± 28.42	-63 ± 43.29	< 0.05
P-Value	0.839	0.945	

Table (5) Comparison between the Middle ear pressures (daPa) measured preoperative and on the 7th postoperative day.

Ear side	Preoperative MEP	Post-operative 7 th day MEP	P-Value
Right	-14.25 ±28.98	-21.25 ± 27.09	0.431
Left	-13.75 ± 28.42	-17.55 ±19.41	0.665
P-Value	0.839	0.554	

Figure 1: Changes in middle ear pressure (daPa) measured preoperative, 1st postoperative day, 3rd postoperative day, and 7th postoperative day.

Discussion :

The middle ear is ventilated by the Eustachian tube (ET), which connects the middle ear to the nasopharynx. The ET's primary function is to balance the air pressure in the middle ear with that of the surrounding atmosphere.¹¹ The ET is thought to have three main functions: middle ear clearance, ventilation, and protection, according to Bluestone and Doyle. Eustachian tube dysfunction may result from any perturbation of these processes.¹² Inadequate swallowing, mechanical obstruction of the tubal orifice, and inflammation of the nasopharyngeal mucosa are the most frequent causes of ET dysfunction.¹³

Traditionally, adenoidectomy is carried out with a curette without the nasopharynx being seen. Removing any residual adenoid tissue, particularly in the tubal and choanal region runs the risk of lacerating the ET.¹⁴ The endoscopic aided adenoidectomy was the logical development of the traditional adenoidectomy as intranasal endoscopy in endoscopic sinus surgery increased.^{6,15}

The primary benefits of endoscopic-assisted adenoidectomy are enhanced direct visualization and magnification throughout the process, prevention of residual tissue with complete removal of the adenoid mass, prevention of needless trauma, superior hemostasis, and increased safety.¹⁶

Radiofrequency adenoid ablation is a suitable, less invasive procedure that results in less pain than blind curettage and minimal blood loss following surgery. The primary advantage of radiofrequency adenoid ablation over other electrical techniques, such as diathermy, is that it results in tissue volumetric reduction over both short and long periods, resulting in mucosal scarring and fibrosis with minimal tissue damage, less heat, and no cutting blades.

Due to the decreased heat generated during tissue ablation (100 Celsius in radiofrequency vs. 300 Celsius in diathermy), bipolar radiofrequency has several major advantages over diathermy, including reduced discomfort and no postoperative bleeding.^{9,17,18}

To our knowledge, the impact of endoscopic radiofrequency adenoid ablation on ME pressure has not been discussed in any literature. Tympanometry was utilized in this study to assess how endoscopic radiofrequency adenoidectomy affected the Eustachian tube function in pediatric patients with adenoid hypertrophy and normal preoperative MEP in the early postoperative phase.

The results of this study revealed that on the first postoperative day, 14 (35%) of 40 patients in our study underwent endoscopic radiofrequency adenoidectomy and had normal preoperative middle ear pressure displayed type C tympanogram in at least one ear. Four patients (10%) had bilateral type C tympanogram on the first postoperative day, while ten patients (25%) had unilateral type C tympanogram. Six (15%) patients had a unilateral type C tympanogram on the third postoperative day, while two (5%) patients had a bilateral type C tympanogram. On the seventh postoperative day, 100% of patients had type A tympanogram and had returned to their prior middle ear pressure. None of the patients had a Type B tympanogram that could be detected. No complaints of otalgia, aural fullness, or hearing loss were made.

Previous studies have demonstrated that nasal surgery like septoplasty, anterior nasal packing, posterior nasal packing, prolonged nasotracheal intubation, and nasogastric intubation all resulted in MEP decrease (in at least one ear). After the packs and tubes were removed, MEP significantly improved

and returned to its previous state. These researchers hypothesized that the change in MEP was most likely caused by, direct occlusion of the ET by nasal packing, the effect of surgery, edema of the nasopharyngeal mucosa, inflammatory mucosal reaction, or tubal occlusion by excessive seromucous gland secretions in the medial part of the ET.^{19,20}

According to Bonding and Tos, after a tonsillectomy, negative MEP occurred in nine out of 15 patients (about 60%). While the other three patients took several days to get back to normal, six patients did so in just two days.¹³ Thirty-nine percent of patients had transiently negative MEP on the first postoperative day after tonsillectomy. Holt et al. used tympanometry to measure the MEP of 22 individuals after tonsillectomy, they found significant changes in tympanogram.²² According to these researches, nasopharyngeal and tubal muscle dyscoordination or impaired local lymphatic drainage after surgery may both contribute to ET dysfunction.

Unlu et al. found that 75% of patients who had adenotonsillectomy or adenoidectomy using the curettage procedure and had normal preoperative MEP experienced at least a unilateral reduction in the MEP on the first postoperative day. On the third postoperative day, 12.5 % of patients had bilateral Eustachian dysfunction, whereas 15.6 % had unilateral Eustachian dysfunction. On the seventh postoperative day, 3.1% of patients had bilateral Eustachian dysfunction, while no patients had unilateral Eustachian dysfunction. Other patients have returned to the MEP readings from before surgery.²³

On the first postoperative day, Atila et al. found an aberrant drop in the MEP in at least one ear in 81.2 percent of patients who underwent curettage

adenoidectomy. On the seventh postoperative day, 6.2 percent and 3.1 percent of patients, respectively, had unilateral and bilateral ET tube malfunction.²⁴

According to Abou-Elhamd, 57 % of patients who had conventional adenoidectomy experienced type C tympanogram one day after surgery and fully recovered one month later.²⁵

The surgical site edema in the area around the ET, the presence of residual adenoid tissue around the torus tubarius, blood clots in the immediate postoperative period, or surgical trauma to the ET may be the causes of Eustachian tube dysfunction that developed after curettage adenoidectomy.²⁴

The direct visualization of the surgical field provided by endoscopic radiofrequency adenoidectomy has several benefits, including a reduction in the likelihood of residual lymphoid tissues, more effective bleeding control with less blood loss, a shorter operating time, and protection against damage to the Eustachian tube that could result in its fibrosis. In our study, the transitory reduction in MEP that occurred after an endoscopic radiofrequency adenoidectomy was reversed on the seventh postoperative day. ET dysfunction may be brought on by the edema at the surgical site in the vicinity of the Eustachian tube. Concerning ET dysfunction and the absence of ear complaints, endoscopic radiofrequency adenoidectomy is a safe procedure. The lack of a control group is the study's main drawback.

Conclusion:

Transient and temporary negative middle ear pressure occurs in the early postoperative period following endoscopic radiofrequency adenoidectomy in children. The surgical

site edema, particularly around ET, maybe the cause of this temporary Eustachian dysfunction. Endoscopic radiofrequency adenoidectomy is a safe procedure in terms of ET dysfunction.

Reference:

1. Bidaye R, Vaid N, Desarda K. Comparative analysis of conventional cold curettage versus endoscopic assisted coblation adenoidectomy. *J Laryngol Otol.* 2019;133(4):294-299. doi:10.1017/S0022215119000227
2. Sjogren PP, Thomas AJ, Hunter BN, Butterfield J, Gale C, Meier JD. Comparison of pediatric adenoidectomy techniques. *The Laryngoscope.* 2018;128(3):745-749. doi:10.1002/lary.26904
3. Shapiro NL, Bhattacharyya N. Cold Dissection Versus Coblation-Assisted Adenotonsillectomy in Children. *The Laryngoscope.* 2007;117(3):406-410. doi:10.1097/MLG.0b013e31802ffe47
4. Naguib N. Endoscopic examination after adenoidectomy: is it necessary? *Egypt J Otolaryngol.* 2013;29(2):76-79. doi:10.7123/01.EJO.0000426361.77319.2a
5. Somani SS, Naik CS, Bangad SV. Endoscopic Adenoidectomy with Microdebrider. *Indian J Otolaryngol Head Neck Surg.* 2010;62(4):427-431. doi:10.1007/s12070-011-0118-9
6. Becker SP, Roberts N, Coglianese D. Endoscopic adenoidectomy for relief of serous otitis media. *The Laryngoscope.* 1992;102(12):1379-1384. doi:10.1288/00005537-199212000-00014
7. Pagella F, Pusateri A, Giourgos G, Matti E. Evolution of the Adenoidectomy in the Endoscopic Era. *IntechOpen;* 2011. doi:10.5772/23177
8. Parsons DS. Rhinologic uses of powered instrumentation in children beyond sinus surgery. *Otolaryngol Clin North Am.* 1996;29(1):105-114.
9. Pang KP, Siow JK. Sutter bipolar radiofrequency volumetric tissue reduction of palate for snoring and mild obstructive sleep apnoea: is one treatment adequate? *J Laryngol Otol.* 2009;123(7):750-754. doi:10.1017/S0022215109004253
10. Jerger J. Clinical Experience With Impedance Audiometry. *Arch Otolaryngol.* 1970;92(4):311-324. doi:10.1001/archotol.1970.04310040005002
11. Bylander A, Ivarsson A, Tjernström ö. Eustachian Tube Function in Normal Children and Adults. *Acta Otolaryngol (Stockh).* 1981;92(1-6):481-491. doi:10.3109/00016488109133287
12. Bluestone CD, Doyle WJ. Anatomy and physiology of eustachian tube and middle ear related to otitis media. *J Allergy Clin Immunol.* 1988;81(5, Part 2):997-1003. doi:10.1016/0091-6749(88)90168-6
13. Bonding P, Tos M. Middle Ear Pressure During Brief Pathological Conditions of the Nose and Throat. *Acta Otolaryngol (Stockh).* 1981;92(1-6):63-69. doi:10.3109/00016488109133238
14. Buchinsky FJ, Lowry MA, Isaacson G. Do adenoids regrow after excision? *Otolaryngol Head Neck Surg.* 2000;123(5):576-581. doi:10.1067/mhn.2000.110727
15. Cannon CR, Replogle WH, Schenk MP. Endoscopic-assisted Adenoidectomy. *Otolaryngol Neck Surg.* 1999;121(6):740-744. doi:10.1053/hn.1999.v121.a98201
16. Regmi D, Mathur NN, Bhattarai M. Rigid endoscopic evaluation of conventional curettage adenoidectomy. *J Laryngol Otol.* 2011;125(1):53-58. doi:10.1017/S0022215110002100
17. Vogt K, Daine-Loza I, Sperga M. Comparison of the thermal effects of Coblation and Radiofrequency waves in a porcine turbinate model. *Romanian J Rhinol.* 2018;8(31):157-164. doi:10.2478/rjr-2018-0017
18. Elzayat S, Elsherif H, Aouf M. Transoral endoscopic assisted radiofrequency for adenoid ablation; A randomized prospective comparative clinical study. *Auris Nasus Larynx.*

- 2021;48(4):710-717.
doi:10.1016/j.anl.2020.11.010
- 19.Thompson AC, Crowther JA. Effect of nasal packing on Eustachian tube function. *J Laryngol Otol.* 1991;105(7):539-540.
doi:10.1017/S0022215100116548
- 20.Wake M, McCullough DE, Binnington JD. Effect of nasogastric tubes on eustachian tube function. *J Laryngol Otol.* 1990;104(1):17-19.
doi:10.1017/s0022215100111673
- 21.Hone S w., Moodley S, Donnelly M j., Fenton J e., Gormley P k., Walsh M. The effect of tonsillectomy on eustachian tube function. *Clin Otolaryngol Allied Sci.* 1997;22(6):511-514.
doi:10.1046/j.1365-2273.1997.00062.x
- 22.Holt GR, Watkins TM, Yoder MG, Garcia A. The Effect of Tonsillectomy on Impedance Audiometry. *Otolaryngol Neck Surg.* 1981;89(1):20-26. doi:10.1177/019459988108900105
- 23.Unlu I, Unlu EN, Kesici GG, et al. Evaluation of middle ear pressure in the early period after adenoidectomy in children with adenoid hypertrophy without otitis media with effusion. *Am J Otolaryngol.* 2015;36(3):377-381.
doi:10.1016/j.amjoto.2015.01.005
- 24.Atilla MH, Kaytez SK, Kesici GG, Baştımur S, Tuncer S. Comparison between curettage adenoidectomy and endoscopic-assisted microdebrider adenoidectomy in terms of Eustachian tube dysfunction. *Braz J Otorhinolaryngol.* 2020;86:38-43.
doi:10.1016/j.bjorl.2018.08.004
- 25.Abou-Elhamd kamal E. Effect of tonsillectomy, adenoidectomy or adenotonsillectomy on Eustachian tube function. *Saudi J Oto-Rhino-Laryngol Head Neck Surg.* 2007;9:11-14.